

# Parotidectomy-related facial nerve lesions: proposal for a modified Sunnybrook Facial Grading System

Lesões do nervo facial relacionadas à parotidectomia: proposta de um sistema Sunnybrook de graduação facial modificado

Márcia Gonçalves e Silva Targino da COSTA<sup>1</sup>, Péricles de Andrade MARANHÃO-FILHO<sup>2</sup>, Izabella Costa SANTOS<sup>3</sup>, Ronir Raggio LUIZ<sup>4</sup>, Maurice Borges VINCENT<sup>5</sup>

## ABSTRACT

Facial nerve injury, affecting mainly the marginal mandibular branch, is the most frequent neurologic complication from parotidectomy. **Objective:** To test a modified Sunnybrook Facial Grading System as a new tool to assess the facial nerve function following parotidectomy, emphasizing the marginal mandibular branch. **Methods:** We reviewed the medical records of 73 post-parotidectomy patients (40 female, 18-84 years old, mean age 53.2 years) with facial nerve sparing, referred to the Department of Physical Therapy. All patients had parotid neoplasms or advanced skin cancer, and were followed by the principal author between 2006 and 2014. **Results:** The muscles innervated by the marginal mandibular branch were the most frequently affected (72.6%), particularly in patients undergoing neck dissection ( $p = 0.023$ ). The voluntary movement scores obtained with the modified system were significantly lower compared with the original version ( $p < 0.001$ ). The best and worst scores were observed in patients with benign parotid tumors and skin cancer, respectively. Patients requiring neck dissection ( $p = 0.031$ ) and resection of other structures ( $p = 0.021$ ) had the lowest scores, evidenced only with the modified version. Patients with malignant tumors had significantly worse ratings, regardless of the Sunnybrook system version. The post-physiotherapy analysis involved 50 patients. The worst facial rehabilitation outcomes were related to the marginal mandibular branch function. **Conclusion:** The modified Sunnybrook Facial Grading System improved the marginal mandibular branch assessment, preserving the evaluation of other facial nerve branches.

**Keywords:** Facial nerve; parotid gland; parotid neoplasms.

## RESUMO

A lesão do nervo facial é a principal complicação neurológica relacionada às parotidectomias e, em geral, o ramo marginal mandibular é o mais frequentemente acometido. **Objetivo:** Testar um Sistema Sunnybrook de Graduação Facial modificado (mS-FGS) como uma nova ferramenta para avaliar a função do nervo facial após a parotidectomia, enfatizando o ramo marginal mandibular. **Métodos:** Estudo retrospectivo, baseado em prontuários de 73 casos (40 do sexo feminino, 18-84 anos, idade média = 53,2), submetidos à parotidectomia, com preservação do nervo facial. Todos os pacientes apresentavam neoplasias parotídeas ou câncer de pele avançado, e foram tratados pela autora principal entre 2006 e 2014. **Resultados:** Neste estudo, os músculos inervados pelo ramo marginal mandibular foram os mais acometidos (72,6% dos casos), principalmente nos pacientes que realizaram esvaziamento cervical ( $p = 0,023$ ). Os Escores de Movimento Voluntário obtidos pelo sistema modificado foram inferiores aos obtidos pelo original ( $p < 0,001$ ). As melhores pontuações foram observadas em pacientes com tumores benignos parotídeos e os piores resultados, naqueles com câncer de pele. Pacientes que necessitaram de esvaziamento cervical e ressecção de outras estruturas, além da parótida, apresentaram escores menores ( $p = 0,031$  e  $p = 0,021$ ), evidenciados apenas pelo sistema modificado. Os tumores malignos geraram escores significativamente menores, independentemente do instrumento empregado. A análise pós fisioterapia envolveu 50 casos. Os piores resultados, após a intervenção fisioterapêutica, também foram observados nos músculos inervados pelo ramo marginal mandibular. **Conclusão:** A avaliação da disfunção facial pós-parotidectomia, através do Sistema Sunnybrook com a modificação proposta permitiu uma apreciação mais detalhada do ramo marginal mandibular, sem prejuízo à avaliação dos demais ramos.

**Palavras-chave:** Nervo facial; glândula parótida, neoplasias parotídeas.






<sup>1</sup>Instituto Nacional de Câncer, Serviço de Fisioterapia, Rio de Janeiro RJ, Brasil;

<sup>2</sup>Universidade Federal do Rio de Janeiro, Hospital Universitário Clementino Fraga Filho, Serviço de Neurologia, Rio de Janeiro RJ, Brasil;

<sup>3</sup>Instituto Nacional de Câncer, Serviço de Cirurgia de Cabeça e Pescoço, Rio de Janeiro RJ, Brasil;

<sup>4</sup>Universidade Federal do Rio de Janeiro, Instituto de Estudos de Saúde Pública, Rio de Janeiro RJ, Brasil;

<sup>5</sup>Eli Lilly and Company, Neuroscience Research, Indianapolis, USA.

Márcia Gonçalves e Silva Targino da Costa  <https://orcid.org/0000-0002-5025-8240>; Péricles de Andrade Maranhão-Filho  <https://orcid.org/0000-0003-2030-547X>; Izabella Costa Santos  <https://orcid.org/0000-0002-6426-2419>; Ronir Raggio Luiz  <https://orcid.org/0000-0002-7784-9905>; Maurice Borges Vincent  <https://orcid.org/0000-0001-5855-6069>

**Correspondence:** Márcia Gonçalves e Silva Targino da Costa; Instituto Nacional de Câncer, Hospital do Câncer I - Serviço de Fisioterapia; Rua Washington Luiz, 35 - Centro; 20230-024 Rio de Janeiro RJ, Brasil; E-mail: mgtargino2@yahoo.com.br

**Conflict of interest:** Maurice Vincent is a stock-holding employee at Eli Lilly and Company.

Received 04 January 2019; Received in final form 01 March 2019; Accepted 24 March 2019.



Parotidectomy, the main treatment for benign or malignant parotid tumors, is also indicated in advanced skin tumors invading the gland or spreading to the parotid lymph nodes<sup>1</sup>.

Surgery involves facial nerve manipulation at its trunk and branches. Although facial nerve preservation is aimed at, especially in patients without previous weakness<sup>2</sup>, the incidence of immediate post-parotidectomy facial nerve dysfunction is high, reaching 14.5% of permanent deficits<sup>3</sup>. Causes may be related to the surgery, or the underlying disease<sup>4,5</sup>. The marginal mandibular branch (MMB) is the most frequently affected<sup>3,5,6,7</sup>, resulting in an inability to show the lower teeth on the affected side due to weakness of the *depressor labii inferioris* (DLI) and *depressor anguli oris* (DAO) muscles<sup>8</sup>.

The Sunnybrook Facial Grading System (S-FGS) was recently recommended as the standard tool for assessing facial nerve dysfunctions<sup>9</sup>. However, the muscles innervated by the MMB are not considered by this instrument.

The objective was to emphasize the importance of the MMB dysfunction as a frequent complication following parotidectomy and propose a modified S-FGS that significantly improves the overall clinical assessment of the facial nerve.

## METHODS

This was a retrospective study involving post-parotidectomy patients with dysfunctional facial nerves, treated at the Physiotherapy Department, National Cancer Institute, Rio de Janeiro, Brazil, between January 2006 and December 2014. During this period, a qualified and experienced physiotherapist (MGSTC) personally followed the study patients. Patients had been referred to the physiotherapy outpatient clinic by surgeons or physiotherapists responsible for inpatient care.

At the first outpatient physiotherapy appointment (median time after surgery: 28 days, interquartile range [IQR]: 21–37), the assessment of the five standard facial expressions (forehead wrinkle, eye closure, smile, snarl and lip pucker) was performed as recommended by the S-FGS. Additionally, the DLI and DAO integrity was evaluated using the same criteria through the command “show the lower teeth”. In edentulous patients, the command was adapted to “turn down the lower lip”. According to the S-FGS, each expression receives a degree ranging from 1 to 5, where 1 means no movement, and 5 means full movement, compared with the normal side. The voluntary movement (VM) score is calculated by adding the individual degrees of movement of the five expressions and multiplying the result by 4. This result forms a composite score with two other components, resting symmetry and synkinesis. For the VM scores, patients with total facial paralysis receive 20 points, and those with normal facial movements get 100 points.

The proposed modified Sunnybrook system (mS-FGS) consisted of removing the “snarl” expression, performed by

the *levator labii superioris* and *levator labii superioris alaeque nasi* muscles (one of the three expressions performed by muscles predominantly innervated by the buccal branch); and inserting the “show the lower teeth” expression, performed by the DLI and DAO muscles, innervated by the MMB. We then calculated the VM score using both the original and mS-FGS versions.

After facial movement assessments, patients with mild dysfunctions and spontaneous recovery were released. The remaining patients started an individualized physiotherapy program, including self-massage and facial mirror exercises, according to treatment-based categories<sup>10,11</sup>. Stretching, for healthy hemiface muscles, was prescribed when necessary. Every patient received a manual containing instructions for home exercises to be performed three times a day, with mirror biofeedback, until complete recovery. In the subsequent appointments, patients with low degrees of facial movement received additional proprioceptive neuromuscular facilitation and stimulation with ice<sup>12,13</sup>. Patients were periodically reassessed, following the same protocol. The mean number of physical therapy appointments was 5.40 (2–11), and the median interval time between the first and last facial evaluations was 133 days (IQR: 53–269). The final analysis involved 50 patients.

The Mann-Whitney and Kruskal-Wallis nonparametric tests were used to contrast the degree of movement in the DLI/DAO and the VM scores (original and modified) with the categorical variables. The Wilcoxon test was used to analyze the difference between original and modified VM scores, and the score variation between the initial and final times. The analyses were performed using an SPSS software version 17. A 95% confidence interval was considered significant.

The research project was approved by the National Cancer Institute Research Ethics Committee under registration number 49889015.0.0000.5274, in October 2015.

## RESULTS

From the initial 175 post-parotidectomy patients, 67 were excluded in the first evaluation, as 10 had received physiotherapy treatment only during hospitalization, and 57 had facial nerve sacrifice at the level of the trunk or branches. Among the remaining 108 patients, 36 were excluded for various reasons (Table 1). The final sample comprised 72 patients originating from 73 cases (one patient was operated on twice): 40 women (54.8%), with a mean age of 53.2 years (18–84 years). By the last evaluation, we had lost patients because of the following reasons: they had been released from physical therapy due to spontaneous recovery (10 patients), abandonment of treatment (eight patients), no proper records of a second evaluation (four patients) and death (one patient).

Parotidectomy was performed because of benign and malignant parotid neoplasms or advanced skin cancer. Clinical and surgical data are depicted in Table 2. About one third of the patients (30.1%) needed resection of other structures beyond the parotid, mostly the preauricular skin.

**Table 1. Patient exclusions.**

Reason	n (%)
Physiotherapy for another disorder (pain, trismus, etc.)	10 (27.0)
Patient treated by another physiotherapist*	7 (18.9)
Lack of voluntary movement evaluation records	7 (18.9)
Resection of facial expressions muscles	5 (13.5)
Cognitive deficit	3 (8.1)
Younger than 18 years	2 (5.4)
Previous facial nerve dysfunction	1 (2.7)
Incomplete medical records	1 (2.7)
Total	36 (100)

\*examined just once by the researcher.

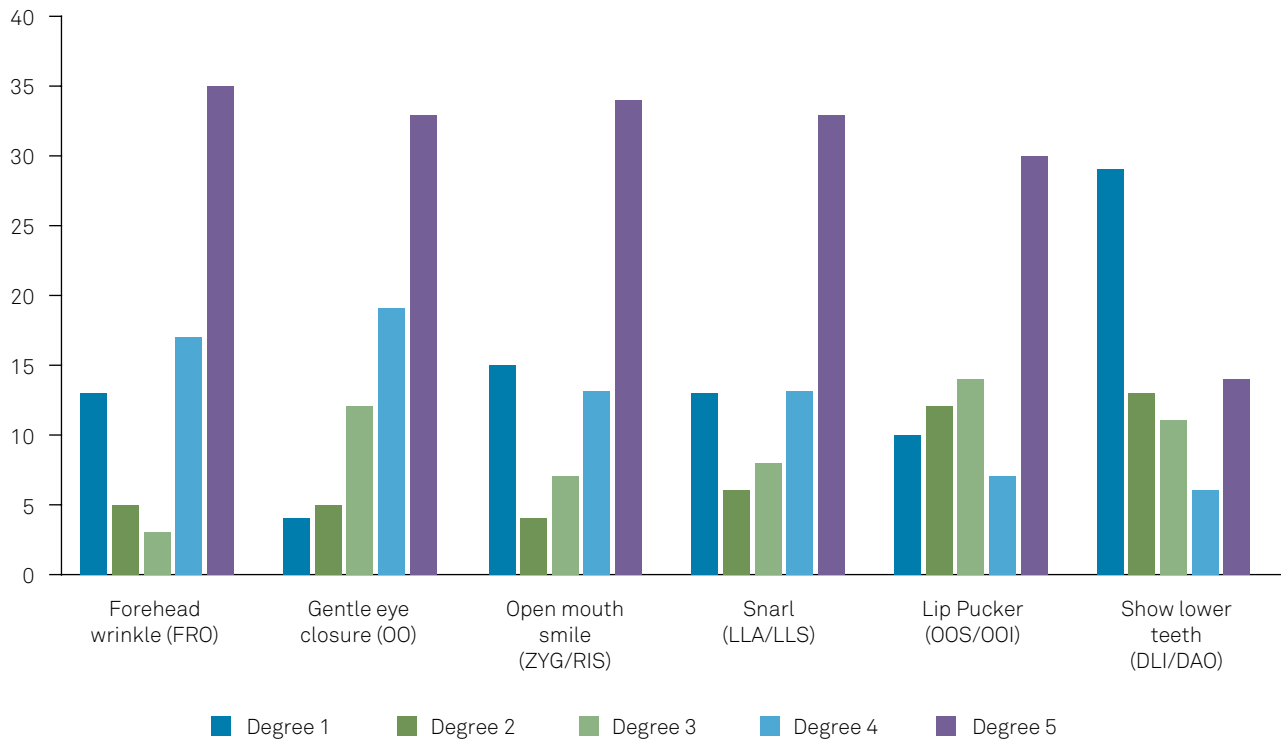
Enlarged procedures included the auricular pavilion (partial or entire), auditory canal, sternocleidomastoid muscle, among others. Reconstruction, required in 23 patients, was performed using techniques selected according to the defect dimension – advancement, unlobed, bilobed, pectoralis major and deltopectoral flaps, among others. In five benign disease patients, the reconstruction with fat graft was used for prevention of Frey’s syndrome. Only one patient had undergone previous radiotherapy. Pleomorphic adenoma was the most frequent benign parotid disease (68.4%). Regarding malignant tumors, mucoepidermoid carcinoma was the major parotid neoplasm (33.3%), whereas squamous cell carcinoma and melanoma accounted for 65% of skin cancers.

Figure 1 shows the distribution of degrees of movement from each evaluated expression. The most affected muscles were the ones innervated by the MMB (DLI/DAO), where the lowest degrees of movement (1–3) were observed in 72.6% of the patients. Almost 40% of these patients received a score of 1 degree (no movement). The second most

**Table 2. Clinical surgical characteristics of the sample (total and subgroups).**

Variables	Median (Q1; Q3) or N (%)			
	Total	Benign parotid	Malignant parotid	Skin cancer
Participants	73 (100)	38 (52.0)	15 (20.6)	20 (27.4)
Age, years	57 (38; 68)	48 (38; 63)	43 (27; 70)	67 (58; 75)
≥60 years old	31 (52.5)	13 (34.2)	4 (26.7)	6 (30)
Sex	40 (54.8)	26 (68.4)	8 (53.3)	6 (30)
Race				
White	41 (56.2)	17 (44.7)	6 (40.0)	18 (90)
Black	12 (16.4)	8 (21.1)	4 (26.7)	0
Brown	19 (26)	12 (31.6)	5 (33.3)	2 (10)
Tumor side				
Right	41 (56.2)	23 (60.5)	7 (46.7)	11 (55)
Left	31 (42.5)	14 (36.8)	8 (53.3)	9 (45)
Bilateral	1 (1.4)	1 (2.6)	0	0
Evolution time, months	16 (10; 36)	24 (11; 60)	24 (8; 36)	12 (5; 24)
Type of parotidectomy				
Superficial	62 (84.9)	33 (86.8)	10 (66.7)	19 (95)
Total	11 (15.1)	5 (13.2)	5 (33.3)	1 (5)
Resection of other structures*	22 (30.1)	0	4 (26.8)	18 (90)
Submandibular gland inclusion	5 (6.8)	0	1 (6.7)	4 (20)
Neck dissection	22 (30.1)	0	7 (46.7)	15 (75)
Dissection of level I	7 (9.6)	0	2 (13.3)	5 (25)
Previous parotid surgery	7 (9.6)	5 (13.2)	2 (13.3)	0
Reconstruction	23 (31.5)	5 (13.2)	4 (26.7)	14 (70)
Adjuvant radiotherapy	14 (19.2)	0	7 (46.7)	7 (35)

\*beyond the gland.



FRO: Frontalis; OO: Orbicularis oculi; ZYG/RIS: Zygomaticus/Risorius; LLA/LLS: Levator labii superioris alaeque nasi/Levator labii superioris; OOS/OOI: Orbicularis oris (superior and inferior); DLI/DAO: Depressor labii inferioris and depressor anguli oris.

**Figure 1.** Distribution of degree of movement in facial expressions – first evaluation. Note a high percentage of patients with the lower degrees in DLI/DAO muscles, an examination that is not included in the original S-FGS.

affected muscle was the *orbicularis oris* (49.3%). In some patients, the inferior portion of this muscle is also innervated by the MMB.

The DLI/DAO movements did not vary according to clinical variables (age, primary site, malignancy). Patients submitted for neck dissection, either in the total sample ( $p = 0.023$ ) or in the malignant parotid subgroup ( $p = 0.054$ ), had statistically significant lower degrees of movement. Patients who required resection of level I lymph nodes (seven patients) and submandibular gland (five patients), both located at the submandibular triangle, also had low DLI/DAO degrees of movement. However, this difference did not reach statistical significance. The five patients who underwent reconstruction with fat graft had higher DLI/DAO degrees of movement ( $p = 0.004$ ). The same was observed in patients with malignant parotid disease, reoperated upon because of tumor recurrence ( $p = 0.038$ ). These findings were unexpected, especially the latter, since the risk of facial nerve damage in re-operations is higher. As re-operations occurred in only two patients, this finding was attributed to chance (Table 3).

The VM scores (five facial expressions assessment) were higher when calculated by the original system (median = 80 points, IQR: 54–100). Patients with benign diseases had higher median scores (92 points) than those with malignant parotid tumors (68 points) and skin cancer (64 points), but this difference was not significant

( $p = 0.071$ ). The VM scores obtained with the mS-FGS were statistically lower in both the total sample and subgroups. Using the mS-FGS, the VM scores were different among subgroups ( $p = 0.036$ ). The 12 patients who underwent more complex surgeries (parotidectomy, resection of other structures, neck dissection and reconstruction) had the lowest median score (50 points; IQR: 41–83). In contrast, the 38 patients with benign disease had the best results (median = 82; IQR: 63–92). Full movement (100 points) was assigned to 20 patients (27.4%) using the original system, contrasting with only 7 (9.7%) using the mS-FGS (Table 4).

Voluntary movement score values (original and modified) were significantly lower in patients with malignant disease, regardless of the instrument used ( $p = 0.022$  and  $p = 0.010$ , respectively). Patients who required neck dissection or resection of other structures beyond the parotid gland had also lower scores, which were only observed with the mS-FGS (Table 5).

In the last evaluation, the outcomes from the 50 remaining patients showed significant improvement in VM scores, regardless of the disease and the system used. However, the worst outcomes were observed in muscles innervated by the MMB, with 17 patients (34%) maintaining the lowest degree of movement (Figure 2). The isolated MMB paresis was observed in 10 patients, eight of them with benign diseases.

**Table 3.** Surgical variables and analysis of degrees of movement of the DLI/DAO.

Variables	Mean (SD) or p-value							
	Total		Benign parotid		Malignant parotid		Skin cancer	
	DLI/DAO	p-value	DLI/DAO	p-value	DLI/DAO	p-value	DLI/DAO	p-value
Parotidectomy								
Superficial	2.6 (1.5)	0.403	2.8 (1.5)	0.376	2.2 (1.4)	0.859	**	**
Total	2.2 (1.6)		2.2 (1.8)		2.4 (1.7)			
Neck dissection								
No	2.8 (1.6)	0.023	*	*	2.9 (1.5)	0.054	2.6 (2.2)	0.866
Yes	1.9 (1.4)				1.6 (1.1)		2.1 (1.5)	
Dissection of level I								
No	2.2 (1.6)	0.332	*	*	2.4 (1.5)	0.571	2.5 (1.8)	0.197
Yes	1.3 (0.5)				1.5 (0.7)		1.2 (0.4)	
Submandibular gland inclusion								
No	2.0 (1.5)	0.967	*	*	**	**	2.4 (1.7)	0.335
Yes	1.5 (0.6)						1.3 (0.5)	
Resection of other structures								
No	2.7 (1.6)	0.060	*	*	2.6 (1.6)	0.343	3.0 (2.8)	0.674
Yes	2.0 (1.4)				1.5 (0.6)		2.1 (1.6)	
Reconstruction								
No	2.5 (1.5)	0.848	2.5 (1.4)	0.004	2.5 (1.6)	0.571	2.8 (2.0)	0.547
Yes	2.5 (1.6)		4.6 (0.5)		1.8 (0.9)		1.9 (1.4)	
Parotid gland reoperation								
No	2.5 (1.6)	0.891	2.9 (1.5)	0.084	1.9 (1.2)	0.038	*	*
Yes	2.4 (1.6)		1.6 (0.9)		4.5 (0.7)			

DLI/DAO: depressor labii inferioris and depressor anguli oris movement grades; Values in bold were statistically significant; \* Not performed; \*\* Not tested. Just one patient underwent some of the procedures.

**Table 4.** Differences between voluntary movement scores assessed by the original and the modified systems – First evaluation.

Variables	Total	Benign parotid	Malignant parotid	Skin Cancer
	n = 73	n = 38	n = 15	n = 20
Original Score				
Average (SD)	74.19 (26.35)	81.47 (21.59)	65.87 (29.28)	66.6 (29.02)
Median (IQR)	80 (54 - 100)	92 (67 - 100)	68 (28 - 92)	64 (44 - 99)
Highest score (100 pts) - n (%)	20 (27.4)	13 (34.2)	2 (13.3)	5 (25.0)
Lowest scores (20-36 pts) - n (%)	10 (13.7)	2 (5.3)	4 (26.7)	4 (20.0)
Modified Score				
Average (SD)	69.70 (23.89)	77.05 (19.61)	61.60 (26.69)	61.8 (25.77)
Median (IQR)	76 (52 - 92)	82 (63 - 92)	68 (32 - 80)	60 (41 - 84)
Highest score (100 pts) - n (%)	7 (9.6)	4 (10.5)	2 (13.3)	1 (5.0)
Lowest scores (20-36 pts) - n (%)	10 (13.7)	2 (5.3)	4 (26.7)	4 (20.0)
Mean difference between scores (min-max)	- 4.49 (-16 to 8)	- 4.42 (-16 to 8)	- 4.26 (-16 to 8)	- 4.80 (-16 to 8)
Difference between scores (p-value)	< 0.001	< 0.001	0.031	0.018

pts: points.

## DISCUSSION

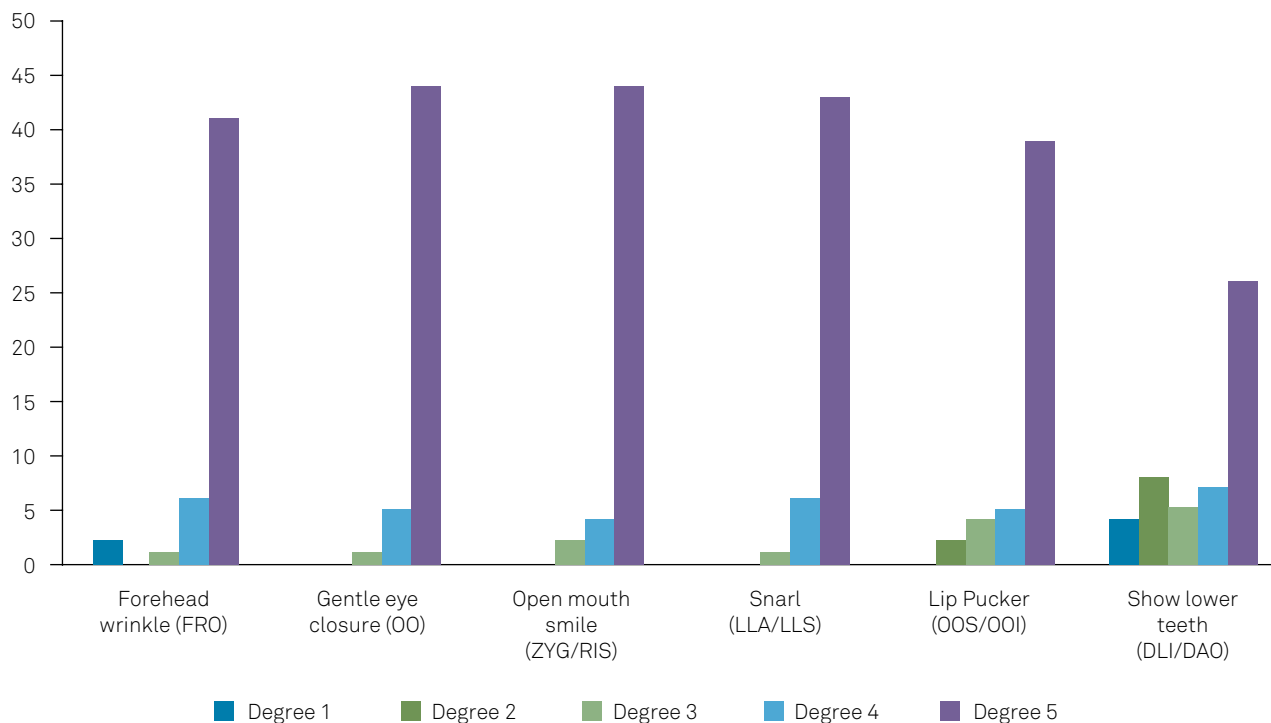
The facial nerve provides innervation for facial expression muscles, and asymmetry is immediately evident and upsetting

following facial nerve lesions<sup>14</sup>. This study showed that a modified version of the S-FGS—the mS-FGS, including evaluation of the DLI and DAO muscles—significantly improved the overall assessment of facial nerve dysfunctions following parotidectomy.

**Table 5.** Analysis of original and modified voluntary movement scores in relation to clinical-surgical variables.


Variable	Original VM Score		Modified VM Score	
	Mean (SD)	p-value	Mean (SD)	p-value
<b>Malignant</b>				
Yes	66.3 (29.0)	0.022	61.7 (25.8)	0.010
No	81.5 (21.6)		77.1 (19.6)	
<b>Disease</b>				
Benign parotid	81.5 (21.6)	0.071	77.1 (19.6)	0.036
Malignant parotid	65.9 (29.9)		61.6 (26.7)	
Skin cancer	66.6 (29.0)		61.8 (25.8)	
<b>Parotidectomy</b>				
Superficial	76.2 (25.6)	0.101	71.6 (23.0)	0.169
Total	62.9 (29.2)		59.3 (27.5)	
<b>Neck dissection</b>				
Yes	66.9 (27.8)	0.121	60.9 (24.0)	0.031
No	77.3 (25.3)		73.5 (23.1)	
<b>Resection of other structures</b>				
Yes	64.4 (29.2)	0.065	59.5 (25.5)	0.021
No	78.4 (24.1)		74.1 (22.0)	
<b>Submandibular gland inclusion</b>				
Yes	57.6 (32.2)	0.251	52.8 (27.6)	0.138
No	75.5 (25.6)		70.9 (23.4)	
<b>Reconstruction</b>				
Yes	70.4 (29.0)	0.556	65.9 (27.0)	0.512
No	75.9 (25.1)		71.4 (22.4)	
<b>Parotid gland reoperation</b>				
Yes	68.6 (25.3)	0.448	65.1 (25.1)	0.554
No	74.8 (26.6)		70.2 (23.9)	

Values in bold were statistically significant.



FRO: Frontalis; OO: Orbicularis oculi; ZYG/RIS: Zygomaticus/Risorius; LLA/LLS: Levator labii superioris alaeque nasi/Levator labii superioris; OOS/OOI: Orbicularis oris (superior and inferior); DLI/DAO: Depressor labii inferioris and depressor anguli oris.

**Figure 2.** Distribution of degrees of movement in facial expressions – last evaluation.



**Figure 3.** Patient on the 35th postoperative day of superficial parotidectomy due to a left benign parotid disease. Using only the original S-FGS, the isolated MMB dysfunction would not be adequately documented. Authorized image.

Several other instruments are available to clinically assess facial nerve impairments<sup>9,15,16</sup>. The most popular is the House-Brackmann Facial Nerve Grading System (HB), which grades the facial nerve function in six levels<sup>17</sup>. This system has received criticism due to the propensity for interobserver variation and low sensitivity to facial changes over the time<sup>18</sup>. Moreover, the HB has limitations in accurately distinguishing different degrees of dysfunction among the facial nerve branches<sup>19-21</sup>. This distinction is indispensable for the physical therapist to plan the best treatment, compare results and predict the functional prognosis. Even the Facial Nerve Grading Scale 2.0 (the revised HB)<sup>22</sup>, which proposes a regional evaluation of the face, does not enable the evaluator to distinguish whether the dysfunction of the oral region is related to the buccal branch, or to the MMB, or both. An adapted HB approach has been used to assess the facial nerve branches post-parotidectomy<sup>23</sup>. However, some aspects of this method were not clear, such as the criteria to objectively differentiate between some discrete nuances of the HB grades (III and IV), and which muscles or facial expressions were selected to assess each branch (especially the buccal).

New instruments have been created, focusing on a more reliable evaluation with greater reproducibility. The S-FGS stands out in this sense<sup>24</sup>. It offers a regional assessment,

considering the face at rest and during movements, beyond the synkinesis, and with good intraobserver and interobserver reliability.<sup>9</sup> The five standard expressions cover the temporal, zygomatic and buccal branches. However, muscles predominantly innervated by the MMB are not included in the system, limiting the test's use for post-parotidectomy assessment (Figure 3). Other instruments include the evaluation of lip depression, such as the Sydney<sup>19</sup>, and Yanagihara<sup>25</sup> facial nerve grading systems, but the S-FGS surpasses them, mainly in relation to the details of other components (resting symmetry and synkinesis).

The post-parotidectomy facial nerve grading system was specifically developed for this purpose<sup>26</sup>, but its applicability and efficiency have not yet been tested by other authors. On the other hand, Fattah et al.<sup>9</sup>, on behalf of the Sir Charles Bell Society, "...recommend widespread adoption of the Sunnybrook Facial Grading Scale as the current standard in reporting outcomes of facial nerve disorders", based on their systematic review of 19 facial nerve grading scales.<sup>9</sup> This excellent tool, however, needs adaptation to better appraise parotidectomy-induced facial dysfunction by including the MMB evaluation. Otherwise, these muscles need to be assessed apart, hindering a consolidated result that would reliably reflect the post-operative facial functional status.

Our attempt to add only the new expression to the S-FGS, without removing any item failed, as the composite score is based on weights. The inclusion of the sixth expression would hinder the maintenance of the individual values and the weights that compose the instrument, completely mischaracterizing it. In contrast, by withdrawing the snarl expression, we counterbalanced the new inclusion. This occurred because the buccal branch, which innervates the muscles of the snarl expression, maintains its integrity tested by two other important expressions: smiling (*zygomaticus* and *risorius* muscles) and lip pucker (*orbicularis oris* muscle). With the new method, the appraisal of the temporal and zygomatic branches, performed by the *frontalis* and *orbicularis oculi* muscles, remains unchanged. Since the cervical branch innervates only the *platysma* muscle, it was not considered here or in the original system. Although the present study emphasized the VM scores, owing to the proposal of the inclusion of the MMB, we reinforced the importance of other S-FGS components, such as resting symmetry, which was not changed. Considering the synkinesis grading, the expressions involved with the more frequent manifestations of aberrant reinnervation (forehead wrinkle, close eyes, and smile) were maintained<sup>27</sup>.

The question arises as why the MMB is the most affected facial nerve branch in parotidectomies. Nichols et al.<sup>28</sup> argued that the reason was related to the fact that the MMB was thinner and longer than nerves that originated from the upper division. The relationship between the extent of facial nerve dissection and subsequent facial paresis was studied by Cannon et al.<sup>3</sup> The longest branch was the MMB (145mm), and, among their 11 patients with transient facial paresis, 10 involved this branch. Another possible reason was the lower number of vertical interconnections evidenced in the inferior branches compared with those in the upper branches<sup>29,30</sup>.

In our study, the MMB was also the most affected, especially in patients with malignant parotid tumors who underwent neck dissection, which imposed an increased risk to the MMB due to the nerve manipulation distal to the parotid gland. This risk is higher during dissection of level I, located in submandibular triangle, although injuries may also occur at the top of level II<sup>31-33</sup>.

Guntinas-Lichius et al.<sup>21</sup> described that among their 79 patients with malignant parotid tumors submitted to total parotidectomy with facial nerve sparing, 76% required neck dissection. Forty patients (51%) presented with MMB dysfunction as evidenced by electromyography<sup>21</sup>. The increased risk to the MMB, by the inclusion of the level IB in the neck dissection of patients undergoing parotidectomy, was also emphasized by Møller et al.<sup>33</sup>. In our sample, patients who required level I dissection presented with a considerable weakness of the MMB muscles, although this did not reach statistical significance.

The high DLI/DAO movement scores in patients who underwent reconstruction with fat graft for prevention of

Frey's syndrome caught our attention. We did not find reports supporting this finding. Speculatively, we believe that these surgeries presented a low technical difficulty if the tumors were small (1.5–3.0 cm), benign (pleomorphic adenomas) and encapsulated, and were completely excised. The mean VM score of these patients was also high (above 92 points, regardless of the S-FGS version used), suggesting low morbidity of the procedure to the facial nerve as a whole.

Concerning the global facial assessment, we found significantly lower VM scores using the mS-FGS, and a statistically-significant difference among the subgroup scores was observed. This difference was expected because enlarged surgeries tend to result in more severe facial nerve damage. Malignant tumors, neck dissection and resection of other structures were associated with lower VM scores, but the last two findings were identified only by the mS-FGS. Worse results in malignant tumors have been justified by more aggressive surgical requirements<sup>34</sup>. Higher incidences of facial weakness were noted in patients with malignant parotid tumors arising from the deep lobe (100%) and in those requiring neck dissection (83%)<sup>35</sup>. Neck dissection was also associated with 3.5-times higher odds of facial palsy<sup>36</sup>. Concerning the resection of other structures, several parotidectomy reports related to skin cancer have addressed the diagnosis, treatment, and prognosis of the disease, but only reported the percentage of sacrifice or preservation of the nerve<sup>37,38,39</sup>. A series comprising 22 operations for cutaneous tumors including intra- and extraparotid nerve dissection showed that "... *the rate of transient facial nerve dysfunction after cutaneous surgery for skin tumors is slightly higher than after superficial or partial parotidectomy for benign parotid gland tumors*"<sup>40</sup>.

We had 13 patients with isolated MMB paresis, most of them secondary to benign diseases that would not have been measured objectively if we had used only the original S-FGS. Patients with isolated MMB paresis (17%), evidenced by electromyography, were reported in a study of 963 parotidectomies for benign diseases<sup>41</sup>. Tung et al.<sup>5</sup> reported that all patients who developed immediate facial weakness after parotidectomy presented with MMB impairment. The percentage of isolated MMB paresis among these patients reached 93%<sup>5</sup>.

The MMB, besides being the most frequently affected, tends to be responsible for most of the permanent dysfunctions<sup>35,41,42</sup>. Likewise, our results revealed a worse MMB recovery in comparison with the other branches. Seventeen patients (34%) maintained the lower DLI/DAO degrees of movement, of whom 6 (35%) had a benign disease, 8 (47%) had skin cancer and 7 (41%) underwent neck dissection. Taken together, the data reinforce the importance of the MMB in the follow-up of parotidectomy patients.

Our study has some limitations. Although the time frame of this retrospective evaluation spanned eight years, the number of patients in each subgroup was small, probably



due to the restrictive inclusion and exclusion criteria. There was no inter-rater evaluation or electromyographic examination. Nevertheless, our results robustly suggest that post-parotidectomy facial nerve dysfunction is not adequately documented using the unmodified S-FGS. The inclusion of a detailed evaluation of the MMB, the most-frequently affected by surgery, makes the system more suitable for the post-parotidectomy assessments. The proposed modification, replacing the snarl expression by showing the lower teeth, enables the evaluation of this branch without hindering the appraisal of the other branches. The adoption of a

standardized instrument, that is able to accurately reflect the global facial function, as well as the different impairments that are possible in each branch, favors a superior rehabilitation follow-up. A prospective study with a larger sample size may confirm the present findings.

In conclusion, the standard facial nerve evaluation tool, the S-FGS, fails to accurately capture dysfunction of the MMB. A modified S-FGS consisting of replacing the “snarl” expression by the “showing the lower teeth” improves the global assessment of the facial nerve involving MMB lesions.

## References

- Gandolfi MM, Slattery W 3rd. Parotid gland tumors and the facial nerve. *Otolaryngol Clin North Am.* 2016 Apr;49(2):425-34. <https://doi.org/10.1016/j.otc.2015.12.001>
- Guntinas-Lichius O. The facial nerve in the presence of a head and neck neoplasm: assessment and outcome after surgical management. *Curr Opin Otolaryngol Head Neck Surg.* 2004 Apr;12(2):133-41. <https://doi.org/10.1097/00020840-200404000-00014>
- Cannon CR, Replogle WH, Schenk MP. Facial nerve in parotidectomy: a topographical analysis. *Laryngoscope.* 2004 Nov;114(11):2034-7. <https://doi.org/10.1097/01.mlg.0000147943.13052.62>
- Dulguerov P, Marchal F, Lehmann W. Postparotidectomy facial nerve paralysis: possible etiologic factors and results with routine facial nerve monitoring. *Laryngoscope.* 1999 May;109(5):754-62. <https://doi.org/10.1097/00005537-199905000-00014>
- Tung BK, Chu PY, Tai SK, Wang YF, Tsai TL, Lee TL, et al. Predictors and timing of recovery in patients with immediate facial nerve dysfunction after parotidectomy. *Head Neck.* 2014 Feb;36(2):247-51. <https://doi.org/10.1002/hed.23287>
- Gaillard C, Périé S, Susini B, St Guily JL. Facial nerve dysfunction after parotidectomy: the role of local factors. *Laryngoscope.* 2005 Feb;115(2):287-91. <https://doi.org/10.1097/01.mlg.0000154735.61775.cd>
- Musani MA, Zafar A, Suhail Z, Malik S, Mirza D. Facial nerve morbidity following surgery for benign parotid tumours. *J Coll Physicians Surg Pak.* 2014 Aug;24(8):569-72.
- Baker DC, Conley J. Avoiding facial nerve injuries in rhytidectomy. Anatomical variations and pitfalls. *Plast Reconstr Surg.* 1979 Dec;64(6):781-95. <https://doi.org/10.1097/00006534-197912000-00005>
- Fattah AY, Gurusinghe AD, Gavilan J, Hadlock TA, Marcus JR, Marres H, et al. Sir Charles Bell Society. Facial nerve grading instruments: systematic review of the literature and suggestion for uniformity. *Plast Reconstr Surg.* 2015 Feb;135(2):569-79. <https://doi.org/10.1097/PRS.0000000000000905>
- Brach JS, VanSwearingen JM. Physical therapy for facial paralysis: a tailored treatment approach. *Phys Ther.* 1999 Apr;79(4):397-404.
- Vanswearingen J. Facial rehabilitation: a neuromuscular reeducation, patient-centered approach. *Facial Plast Surg.* 2008 May;24(2):250-9. <https://doi.org/10.1055/s-2008-1075841>
- Barbara M, Antonini G, Vestri A, Volpini L, Monini S. Role of Kabat physical rehabilitation in Bell's palsy: a randomized trial. *Acta Otolaryngol.* 2010;130(1):167-72. <https://doi.org/10.3109/00016480902882469>
- Adler SS, Beckers D, Buck M. PNF - Facilitação neuromuscular proprioceptiva. 2nd ed. São Paulo: Manole; 2007.
- Gilchrist JM. Seventh cranial neuropathy. *Semin Neurol.* 2009 Feb;29(1):5-13. <https://doi.org/10.1055/s-0028-1124018>
- Chee GH, Nedzelski JM. Facial nerve grading systems. *Facial Plast Surg.* 2000;16(4):315-24. <https://doi.org/10.1055/s-2000-15547>
- Kang TS, Vrabc JT, Giddings N, Terris DJ. Facial nerve grading systems (1985-2002): beyond the House-Brackmann scale. *Otol Neurotol.* 2002 Sep;23(5):767-71. <https://doi.org/10.1097/00129492-200209000-00026>
- House JW, Brackmann DE. Facial nerve grading system. *Otolaryngol Head Neck Surg.* 1985 Apr;93(2):146-7. <https://doi.org/10.1177/019459988509300202>
- Kanerva M, Poussa T, Pitkäranta A. Sunnybrook and House-Brackmann Facial Grading systems: intrarater repeatability and interrater agreement. *Otolaryngol Head Neck Surg.* 2006 Dec;135(6):865-71. <https://doi.org/10.1016/j.otohns.2006.05.748>
- Coulson SE, Croxson GR, Adams RD, O'Dwyer NJ. Reliability of the “Sydney,” “Sunnybrook,” and “House Brackmann” facial grading systems to assess voluntary movement and synkinesis after facial nerve paralysis. *Otolaryngol Head Neck Surg.* 2005 Apr;132(4):543-9. <https://doi.org/10.1016/j.otohns.2005.01.027>
- Yen TL, Driscoll CL, Lalwani AK. Significance of House-Brackmann facial nerve grading global score in the setting of differential facial nerve function. *Otol Neurotol.* 2003 Jan;24(1):118-22. <https://doi.org/10.1097/00129492-200301000-00023>
- Guntinas-Lichius O, Klusmann JP, Schroeder U, Quante G, Jungehuelsing M, Stennert E. Primary parotid malignoma surgery in patients with normal preoperative facial nerve function: outcome and long-term postoperative facial nerve function. *Laryngoscope.* 2004 May;114(5):949-56. <https://doi.org/10.1097/00005537-200405000-00032>
- Vrabc JT, Backous DD, Djalilian HR, Gidley PW, Leonetti JP, Marzo SJ, et al. Facial Nerve Grading System 2.0. *Otolaryngol Head Neck Surg.* 2009 Apr;140(4):445-50. <https://doi.org/10.1016/j.otohns.2008.12.031>
- Infante-Cossio P, Prats-Golczer VE, Lopez-Martos R, Montes-Latorre E, Exposito-Tirado JA, Gonzalez-Cardero E. Effectiveness of facial exercise therapy for facial nerve dysfunction after superficial parotidectomy: a randomized controlled trial. *Clin Rehabil.* 2016 Nov;30(11):1097-107. <https://doi.org/10.1177/0269215515617309>
- Ross BG, Fradet G, Nedzelski JM. Development of a sensitive clinical facial grading system. *Otolaryngol Head Neck Surg.* 1996 Mar;114(3):380-6. [https://doi.org/10.1016/S0194-5998\(96\)70206-1](https://doi.org/10.1016/S0194-5998(96)70206-1)
- Yanagihara N. Grading of facial palsy. *Proceedings of the Third International Symposium on Facial Nerve Surgery.* In: Fisch U, ed. Facial nerve surgery. Amstelveen, The Netherlands: Kugler Medical Publications, 1977. p. 533-5.

26. Stodulski D, Skorek A, Mikaszewski B, Wiśniewski P, Stankiewicz C. Facial nerve grading after parotidectomy. *Eur Arch Otorhinolaryngol*. 2015 Sep;272(9):2445-50. <https://doi.org/10.1007/s00405-014-3196-y>
27. Moran CJ, Neely JG. Patterns of facial nerve synkinesis. *Laryngoscope*. 1996 Dec;106(12 Pt 1):1491-6. <https://doi.org/10.1097/00005537-199612000-00009>
28. Nichols RD, Stine PH, Bartschi LR. Facial nerve function in 100 consecutive parotidectomies. *Laryngoscope*. 1979 Dec;89(12):1930-4. <https://doi.org/10.1288/00005537-197912000-00005>
29. Davis RA, Anson BJ, Budinger JM, Kurth LR. Surgical anatomy of the facial nerve and parotid gland based upon a study of 350 cervicofacial halves. *Surg Gynecol Obstet*. 1956 Apr;102(4):385-412.
30. Baker DC, Conley J. Avoiding facial nerve injuries in rhytidectomy. Anatomical variations and pitfalls. *Plast Reconstr Surg*. 1979 Dec;64(6):781-95. <https://doi.org/10.1097/00006534-197912000-00005> Duplicata da 8
31. Nason RW, Binahmed A, Torchia MG, Thliversis J. Clinical observations of the anatomy and function of the marginal mandibular nerve. *Int J Oral Maxillofac Surg*. 2007 Aug;36(8):712-5. <https://doi.org/10.1016/j.ijom.2007.02.011>
32. Batstone MD, Scott B, Lowe D, Rogers SN. Marginal mandibular nerve injury during neck dissection and its impact on patient perception of appearance. *Head Neck*. 2009 May;31(5):673-8. <https://doi.org/10.1002/hed.21013>
33. Møller MN, Sørensen CH. Risk of marginal mandibular nerve injury in neck dissection. *Eur Arch Otorhinolaryngol*. 2012 Feb;269(2):601-5. <https://doi.org/10.1007/s00405-011-1610-2>
34. Ellingson TW, Cohen JI, Andersen P. The impact of malignant disease on facial nerve function after parotidectomy. *Laryngoscope*. 2003 Aug;113(8):1299-303. <https://doi.org/10.1097/00005537-200308000-00006>
35. Bron LP, O'Brien CJ. Facial nerve function after parotidectomy. *Arch Otolaryngol Head Neck Surg*. 1997 Oct;123(10):1091-6. <https://doi.org/10.1001/archotol.1997.01900100065009>
36. Eviston TJ, Yabe TE, Gupta R, Ebrahimi A, Clark JR. Parotidectomy: surgery in evolution. *ANZ J Surg*. 2016 Mar;86(3):193-9. <https://doi.org/10.1111/ans.13212>
37. Jackson GL, Ballantyne AJ. Role of parotidectomy for skin cancer of the head and neck. *Am J Surg*. 1981 Oct;142(4):464-9. [https://doi.org/10.1016/0002-9610\(81\)90376-7](https://doi.org/10.1016/0002-9610(81)90376-7)
38. Plopper C, Cernea CR, Ferraz AR, Dos Santos LR, Regis AB. Parotidectomy for primary nonparotid diseases. *Otolaryngol Head Neck Surg*. 2004 Oct;131(4):407-12. <https://doi.org/10.1016/j.otohns.2004.02.053>
39. Hong TS, Kriesel KJ, Hartig GK, Harari PM. Parotid area lymph node metastases from cutaneous squamous cell carcinoma: implications for diagnosis, treatment, and prognosis. *Head Neck*. 2005 Oct;27(10):851-6. <https://doi.org/10.1002/hed.20256>
40. Nakamura Y, Teramoto Y, Asami Y, Imamura T, Sato S, Tanaka R, et al. The rate of facial nerve dysfunction and time to recovery after intraparotid and extraparotid facial nerve exposure and protection in head and neck cutaneous tumor surgery. *Int J Clin Oncol*. 2017 Oct;22(5):843-8. <https://doi.org/10.1007/s10147-017-1148-4>
41. Guntinas-Lichius O, Klusmann JP, Wittekindt C, Stennert E. Parotidectomy for benign parotid disease at a university teaching hospital: outcome of 963 operations. *Laryngoscope*. 2006 Apr;116(4):534-40. <https://doi.org/10.1097/01.mlg.0000200741.37460.ea>
42. O'Brien CJ, Petersen-Schafer K, Papadopoulos T, Malka V. Evaluation of 107 therapeutic and elective parotidectomies for cutaneous melanoma. *Am J Surg*. 1994 Nov;168(5):400-3. [https://doi.org/10.1016/S0002-9610\(05\)80084-4](https://doi.org/10.1016/S0002-9610(05)80084-4)